



## *Caso problema:*

# *Luxación protésica inveterada*

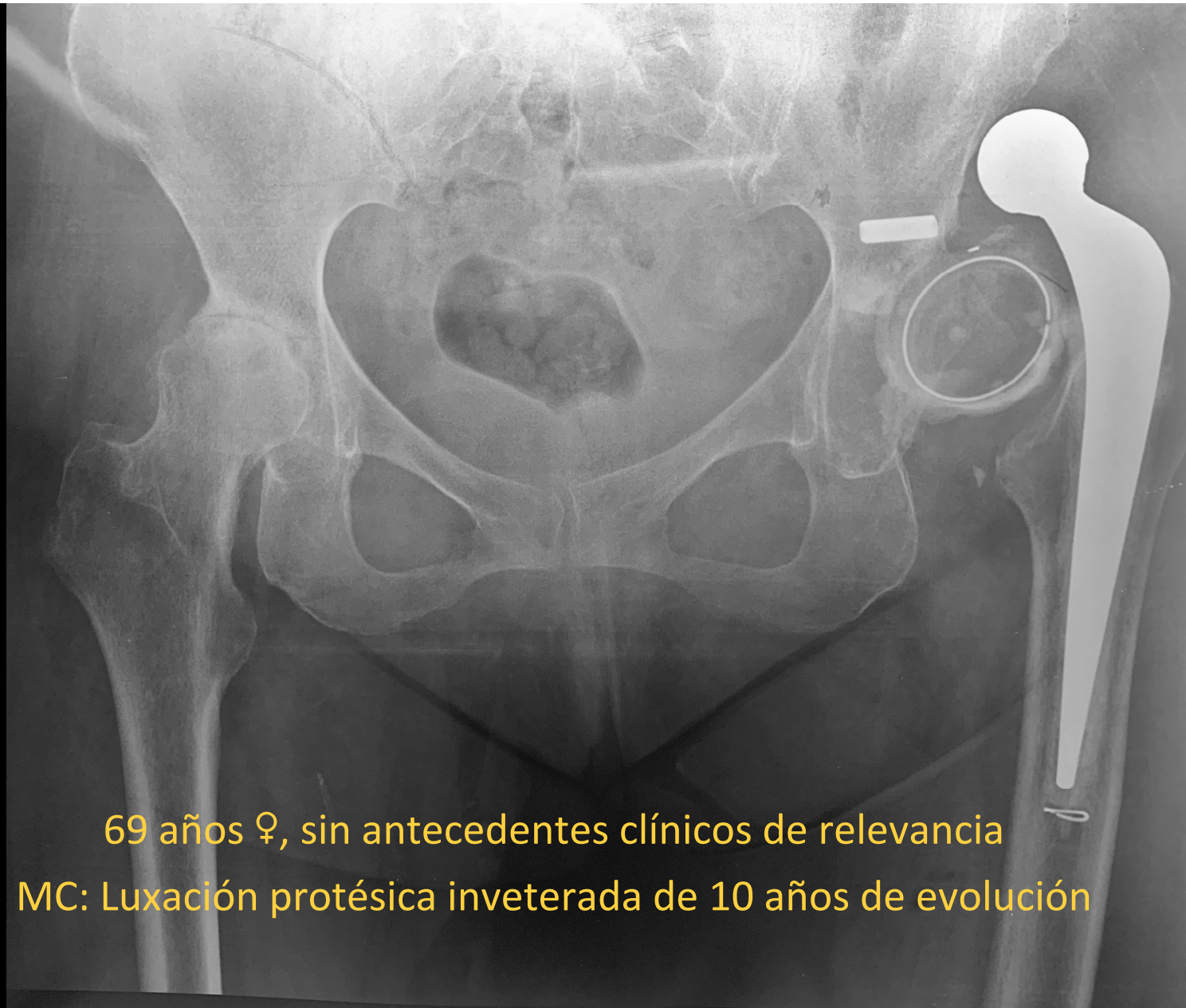***Equipo GRECARO***

*Dr. Tillet Fernando*

*Dr. Bochatay Eduardo*

*Dr. Lopreite Fernando*



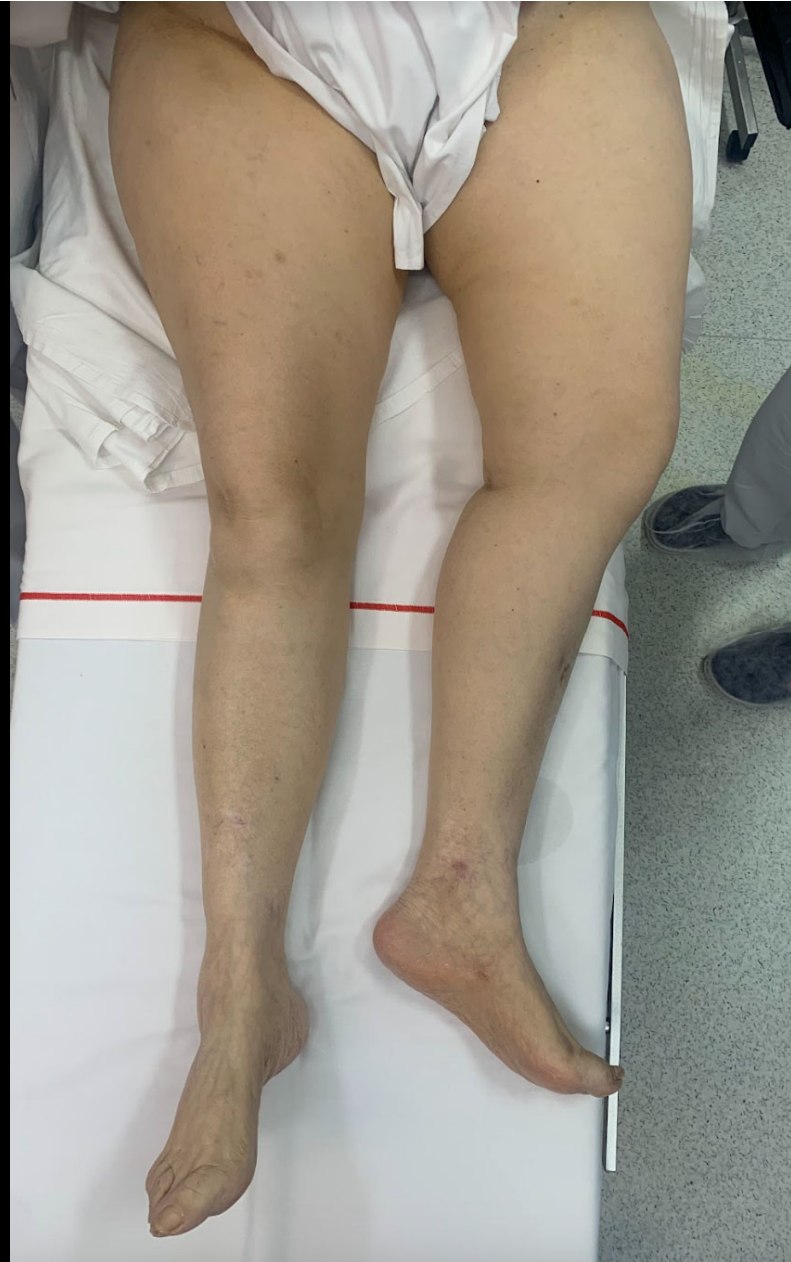


69 años ♀, sin antecedentes clínicos de relevancia

MC: Luxación protésica inveterada de 10 años de evolución

**Examen físico:**

**Acortamiento e  
impotencia funcional de  
mmii izquierdo**

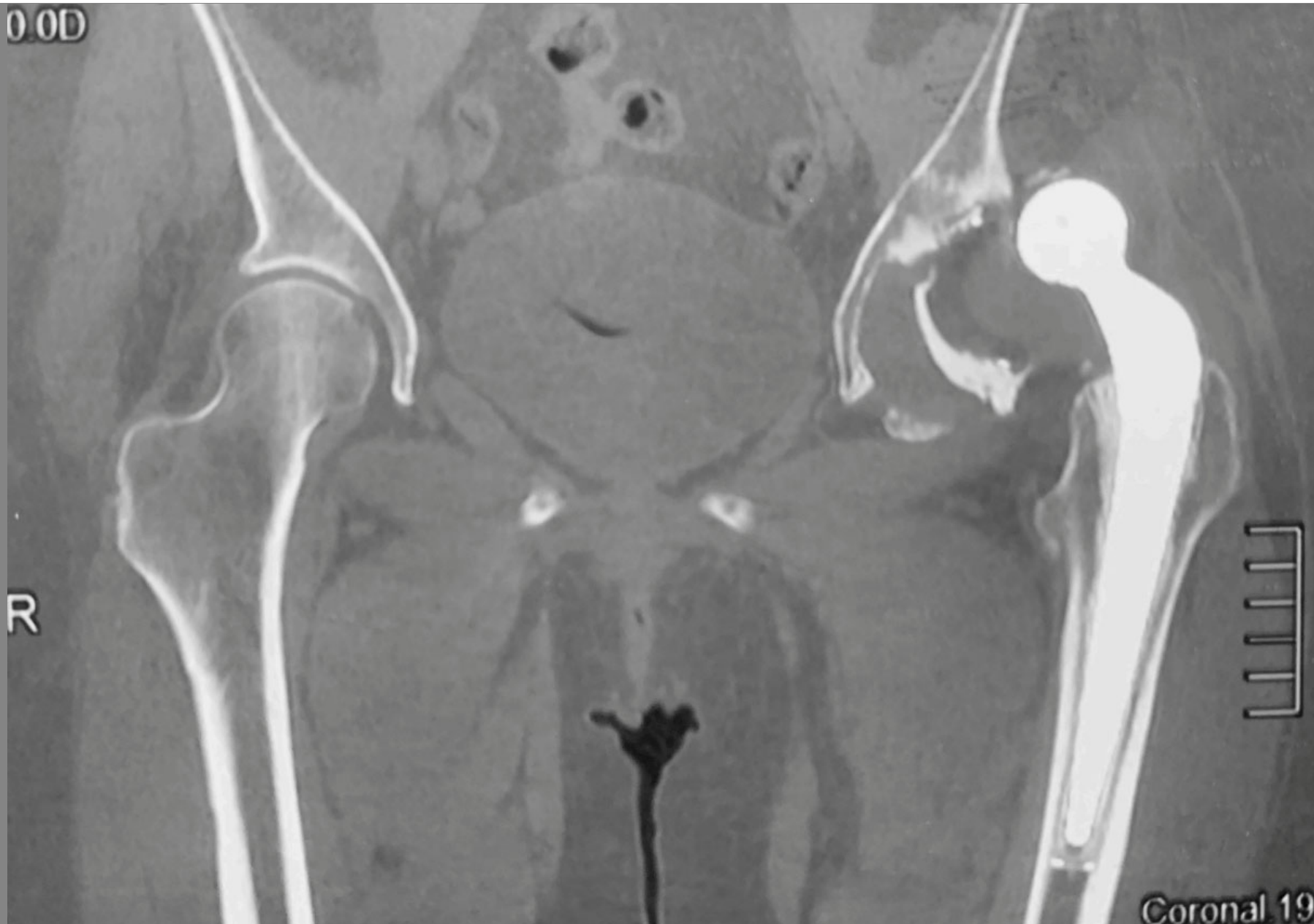

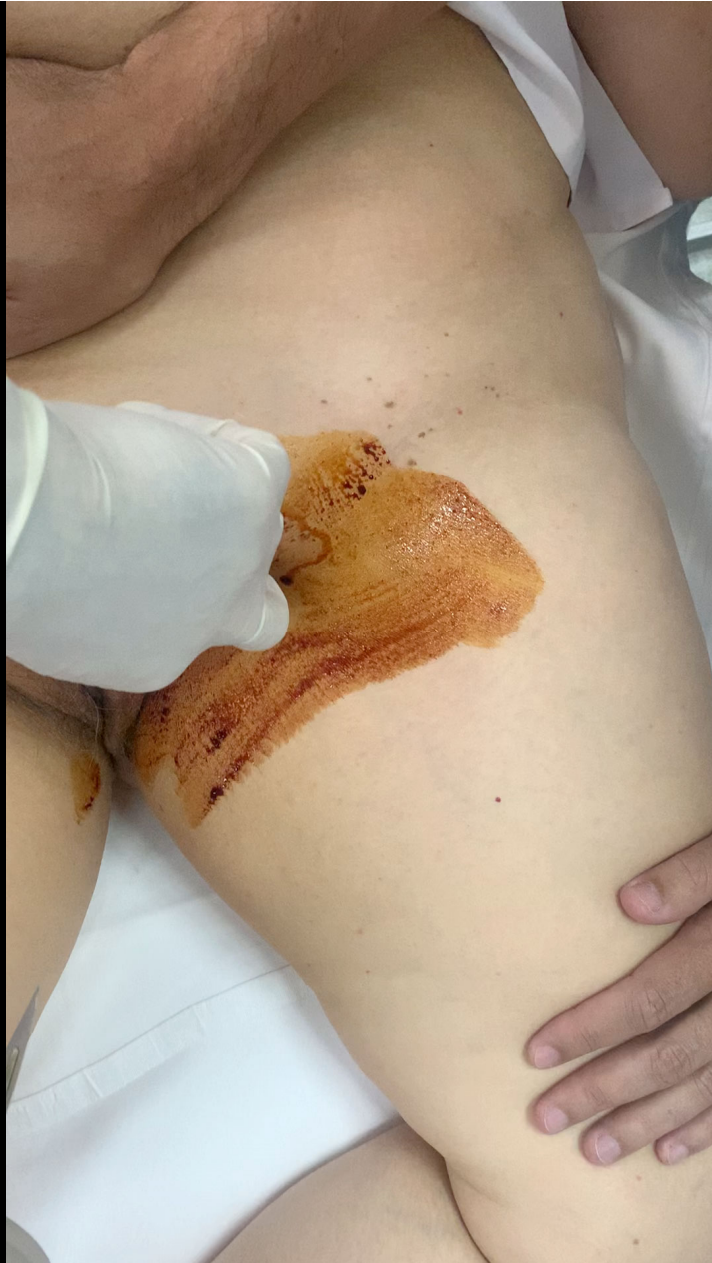0.0D

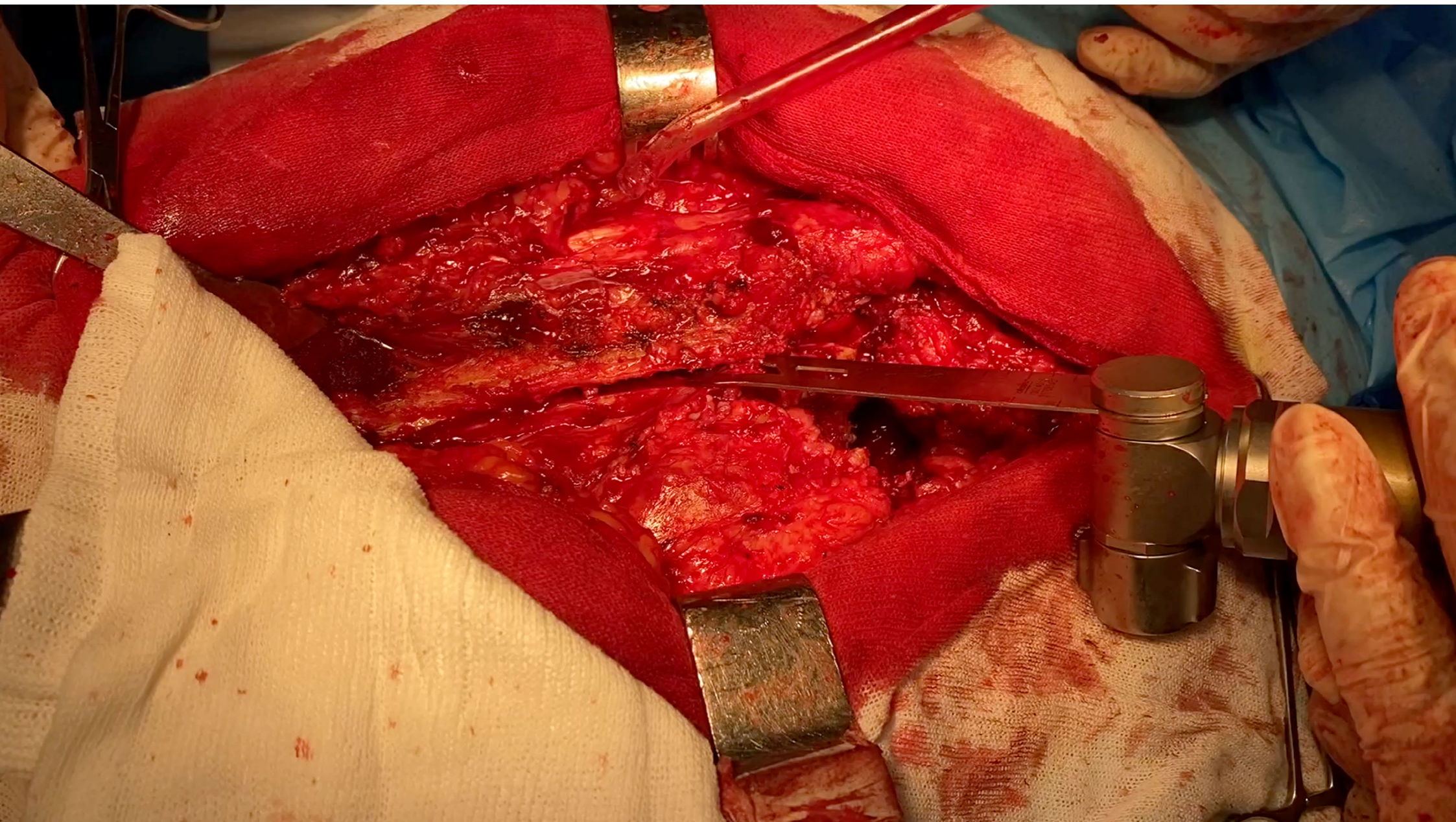
R

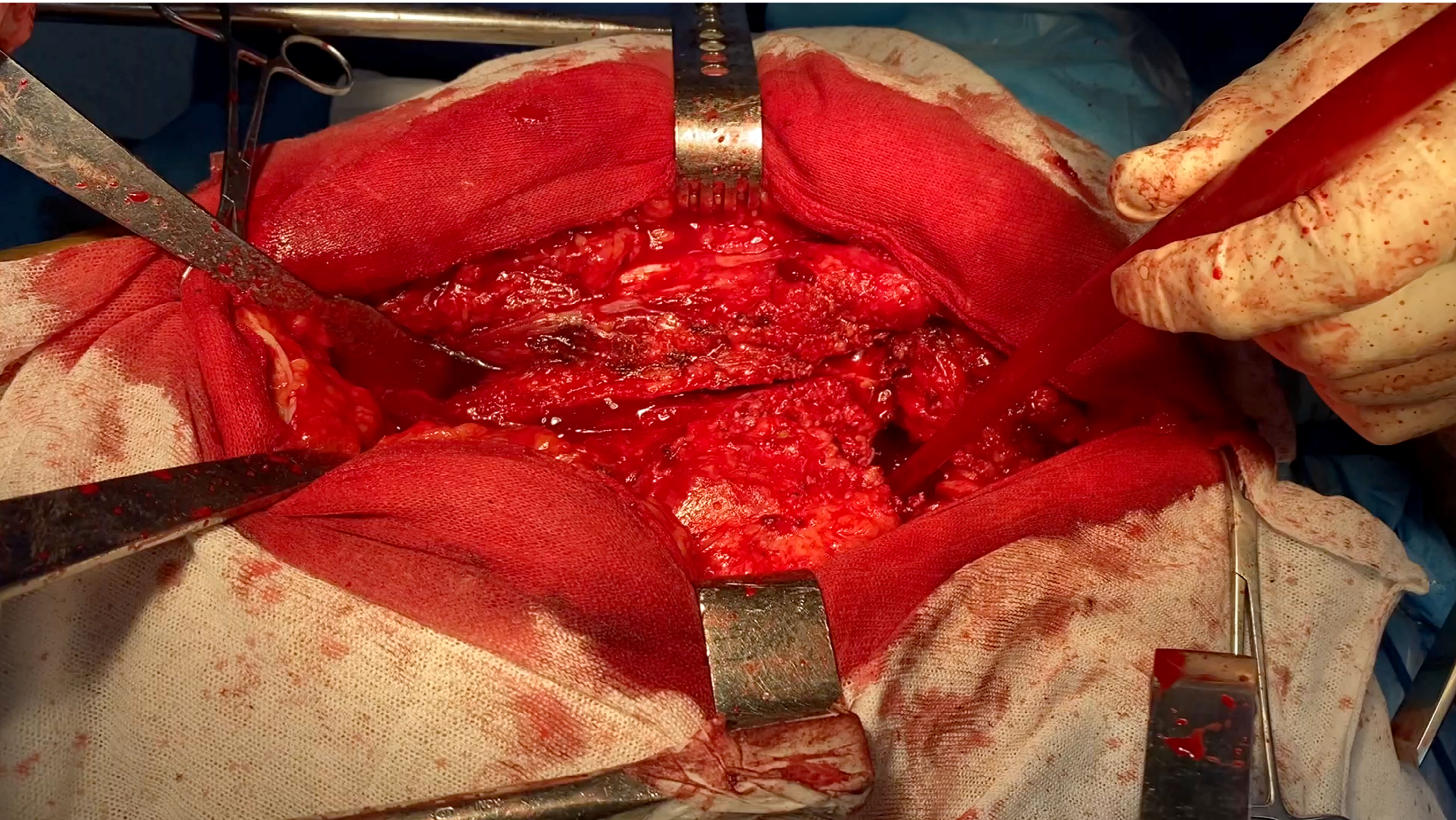


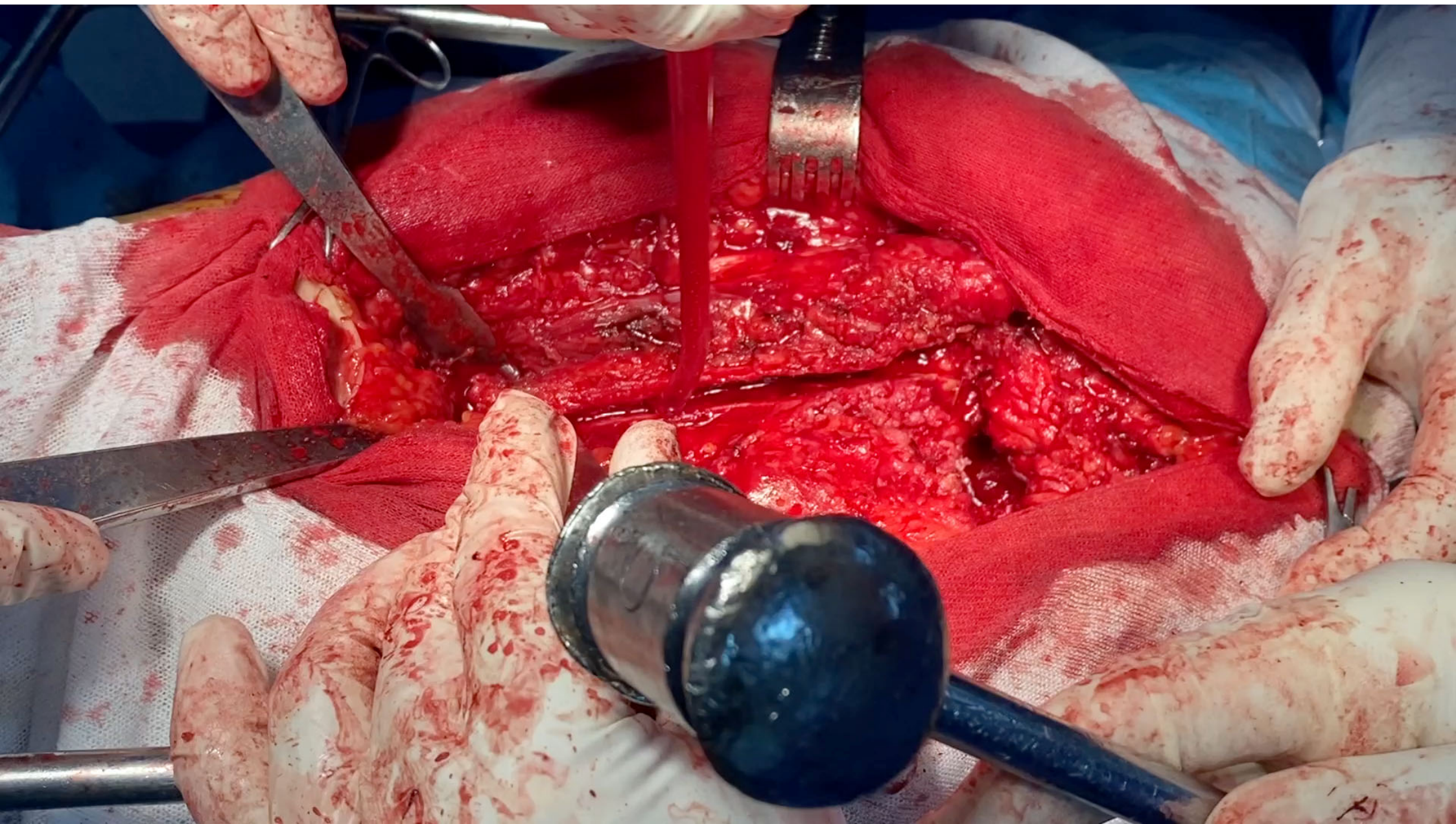
Coronal 19



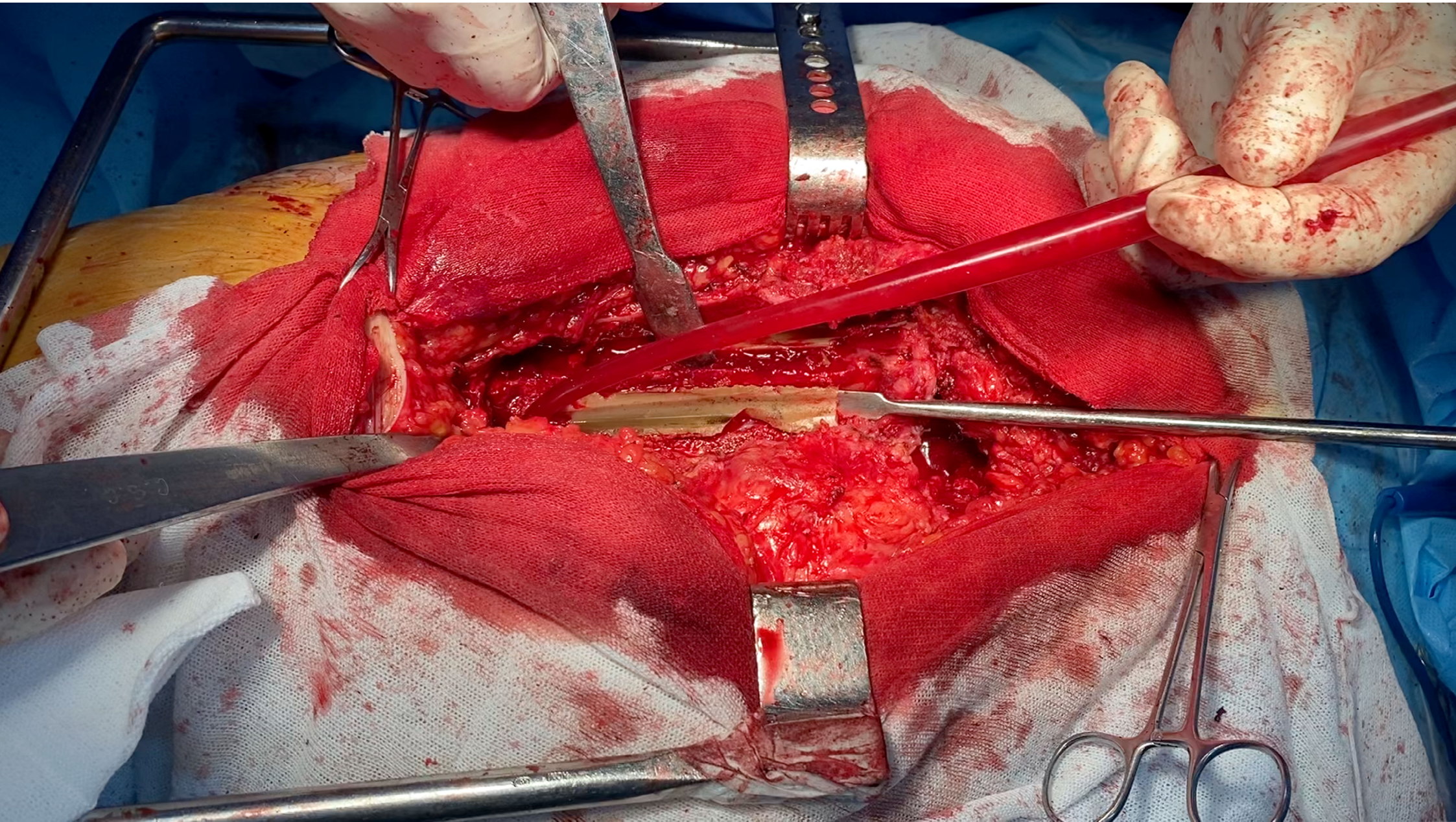


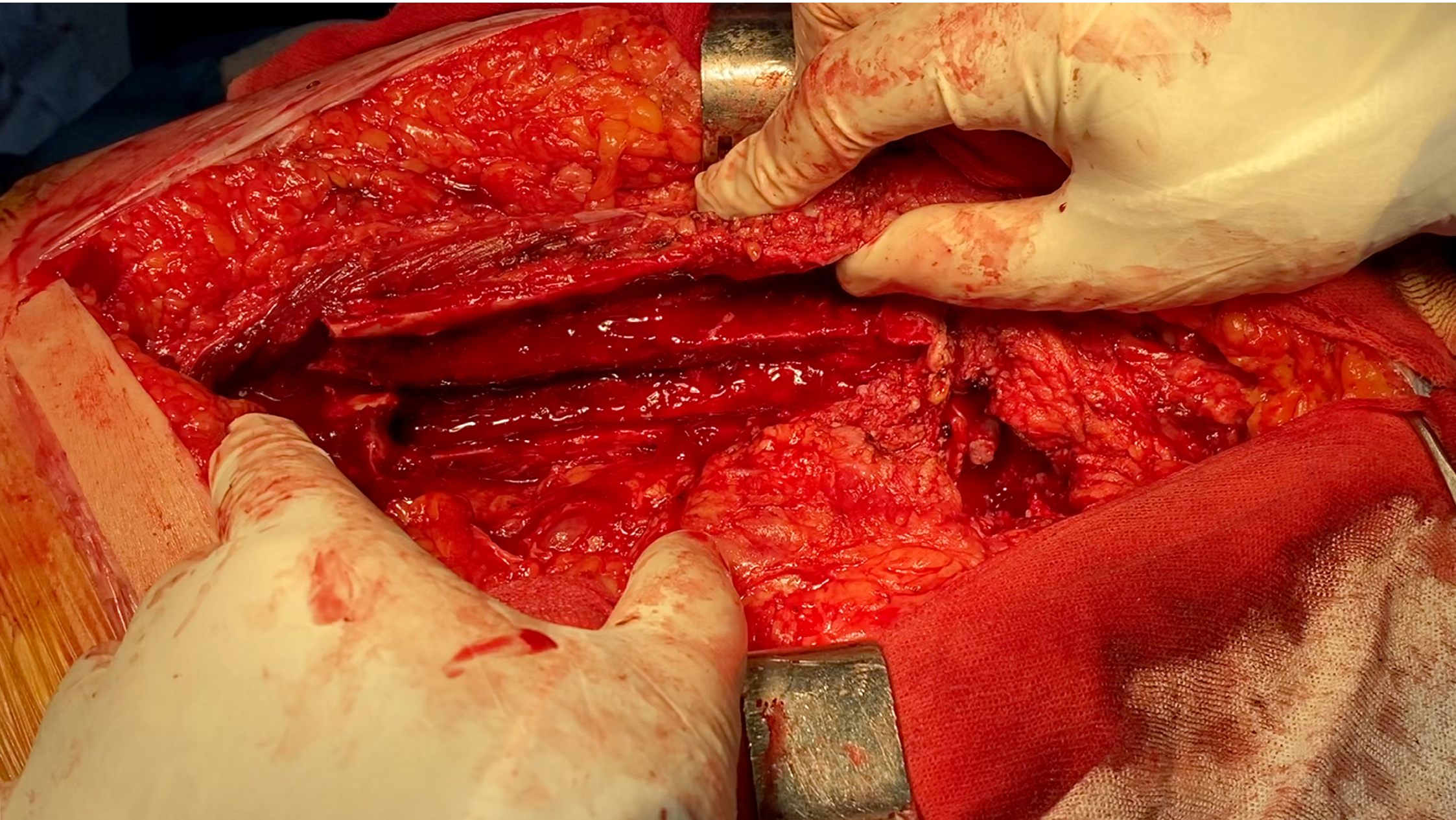


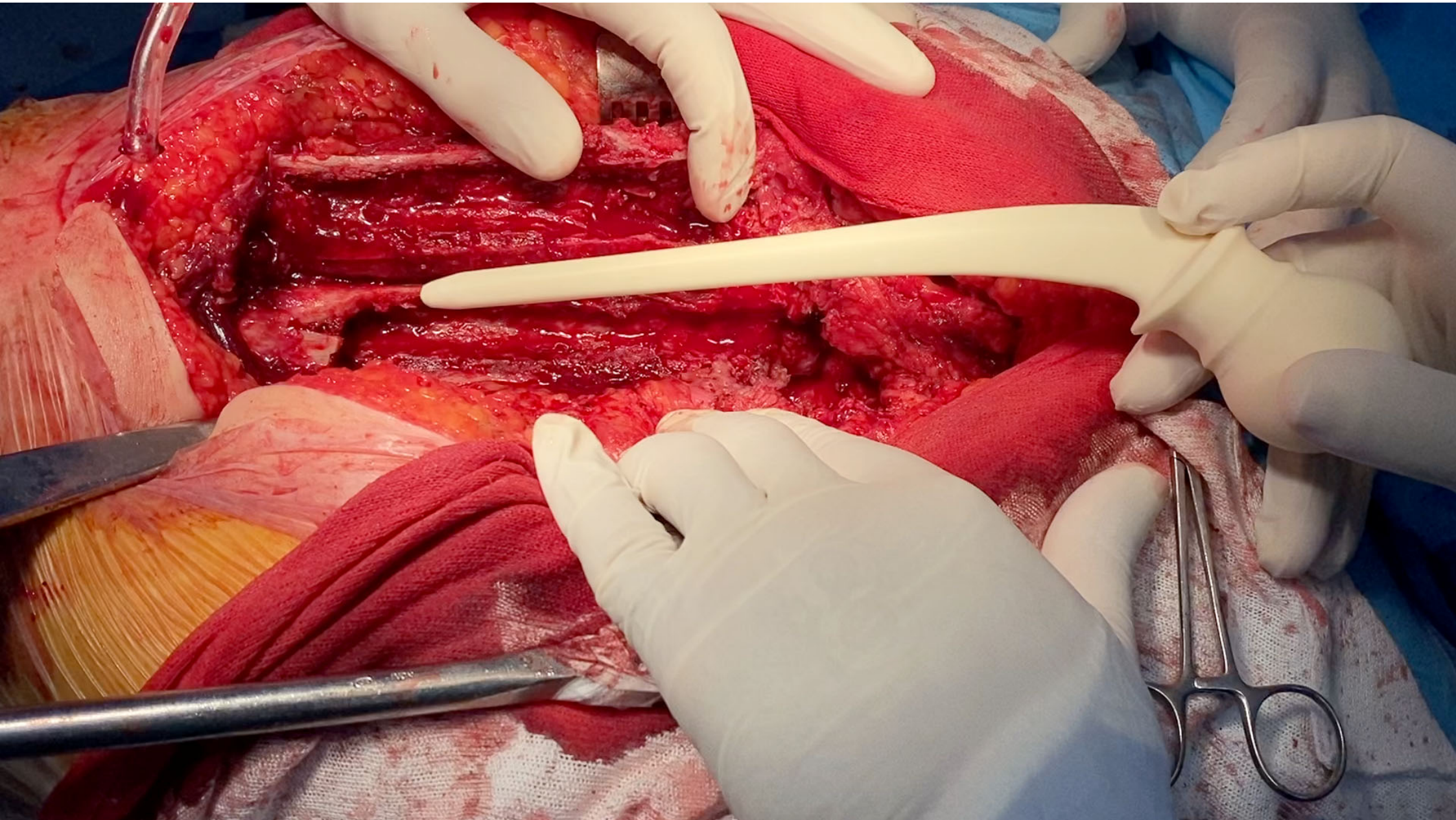


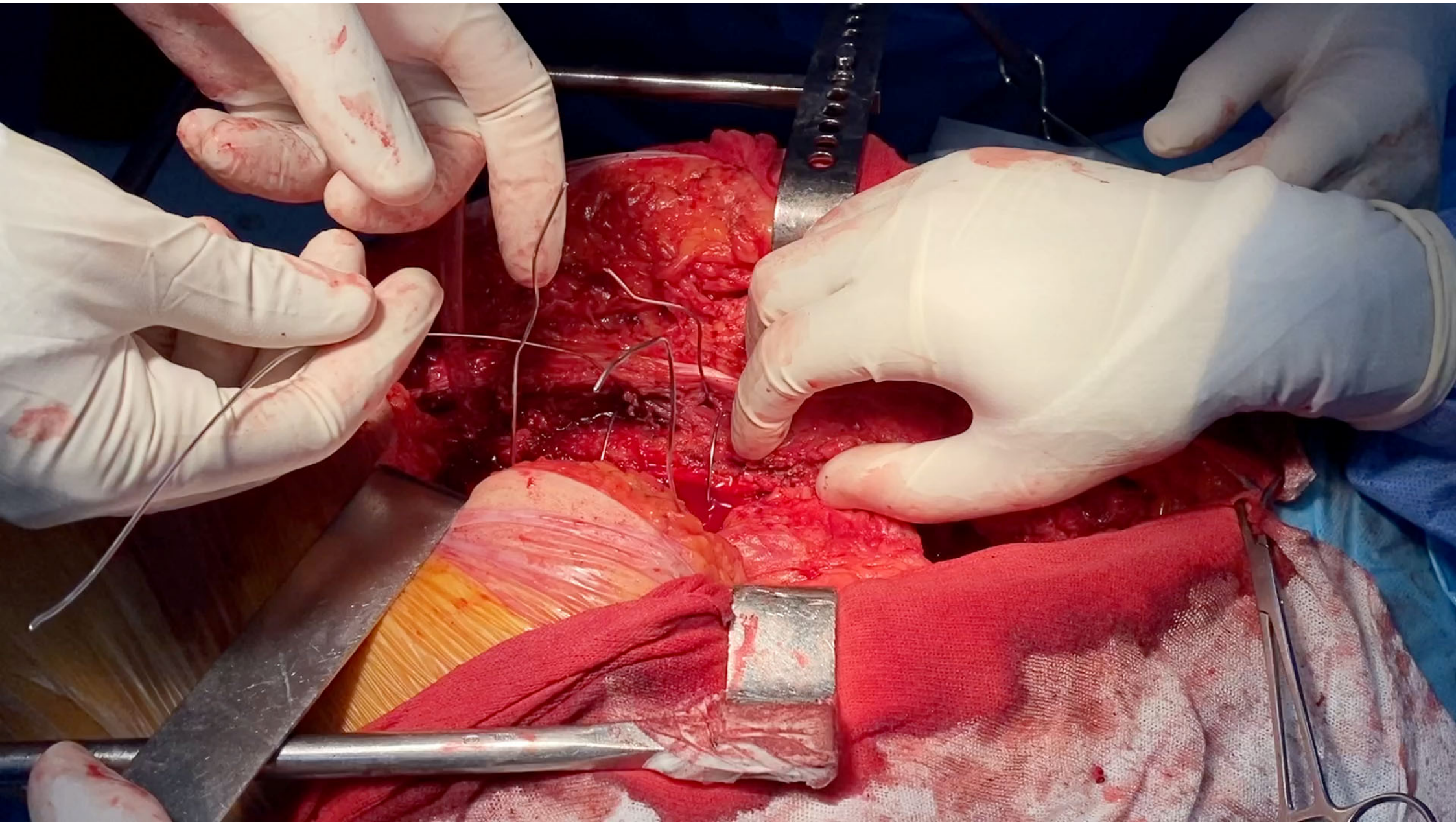


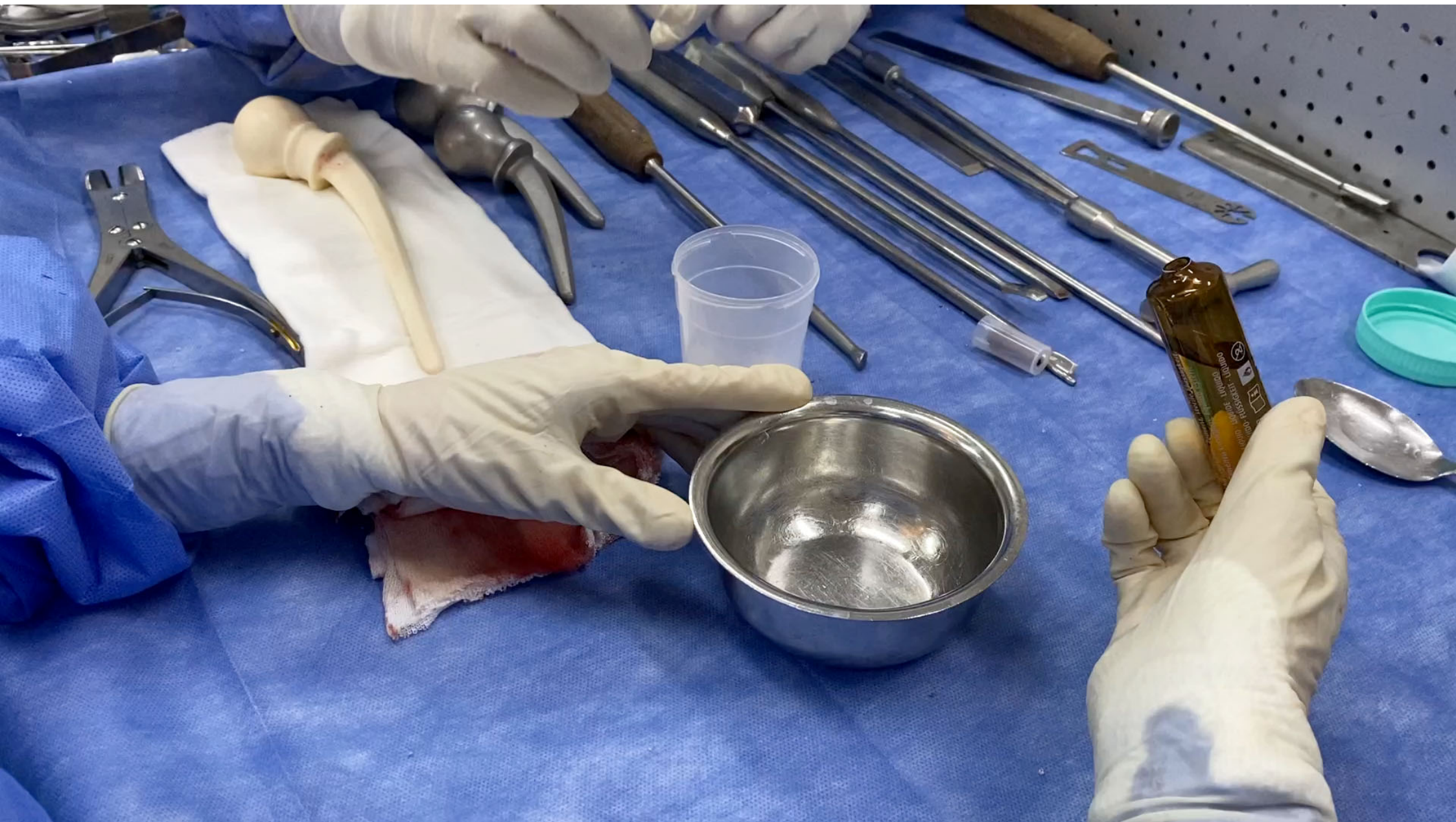


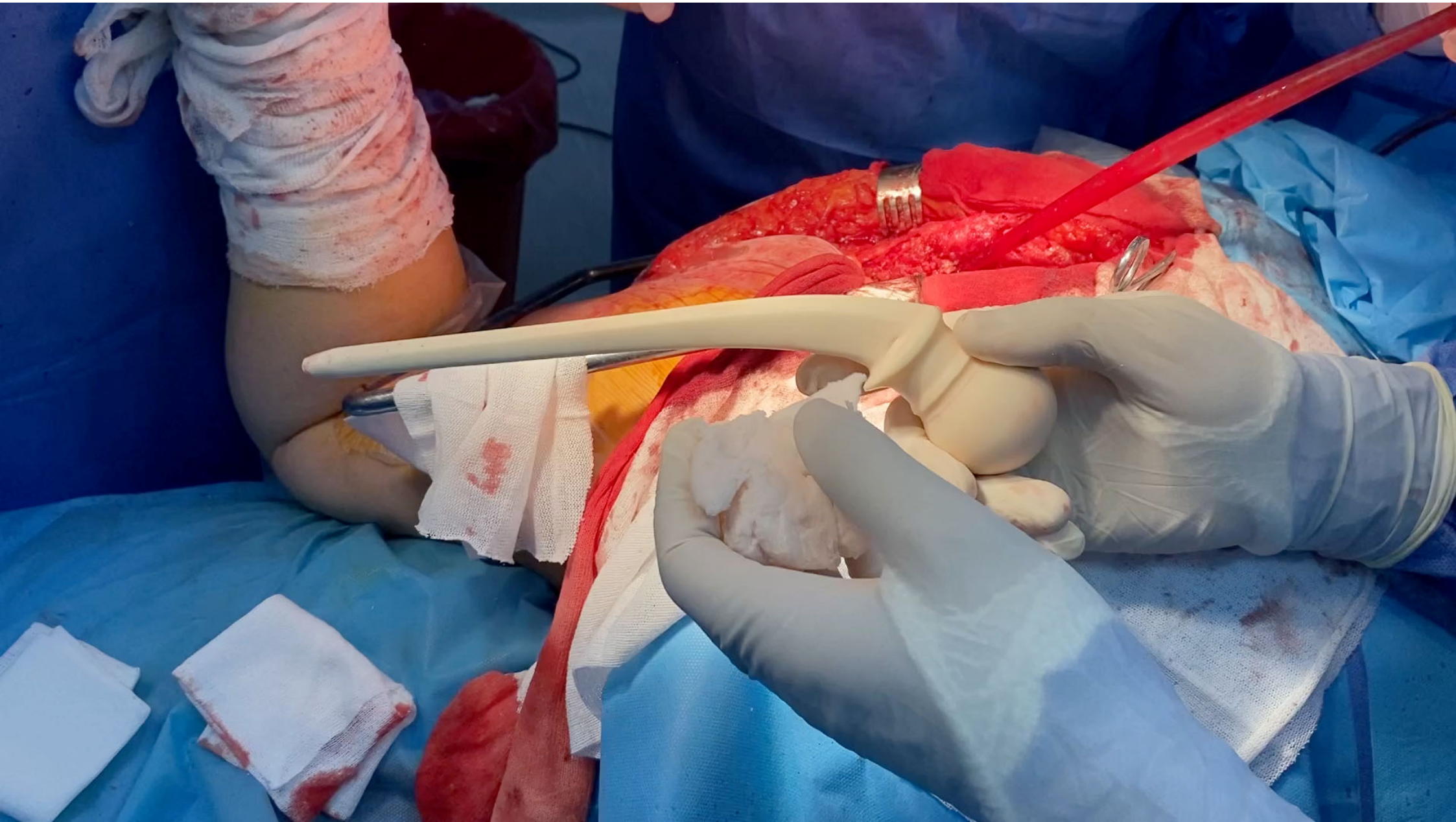


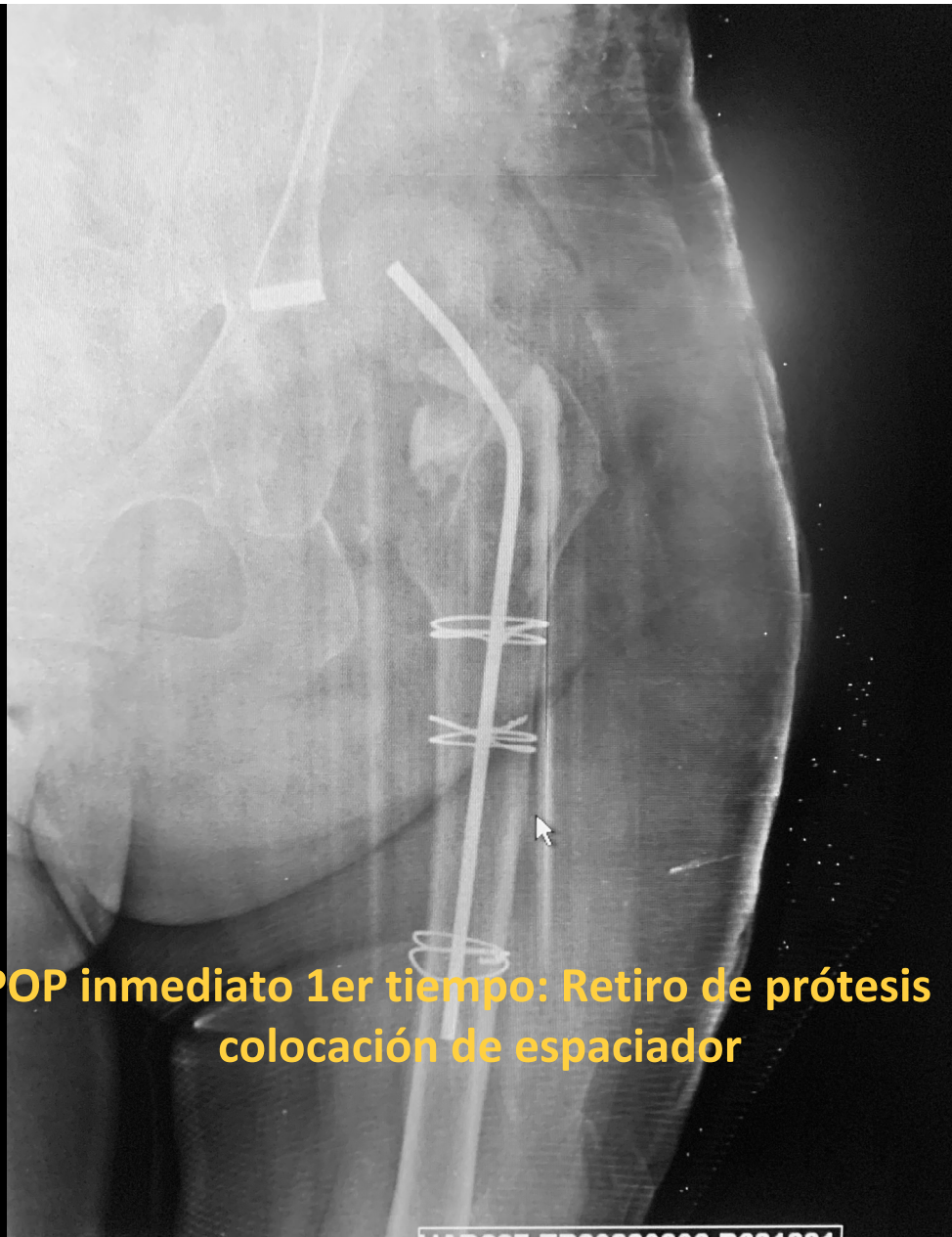



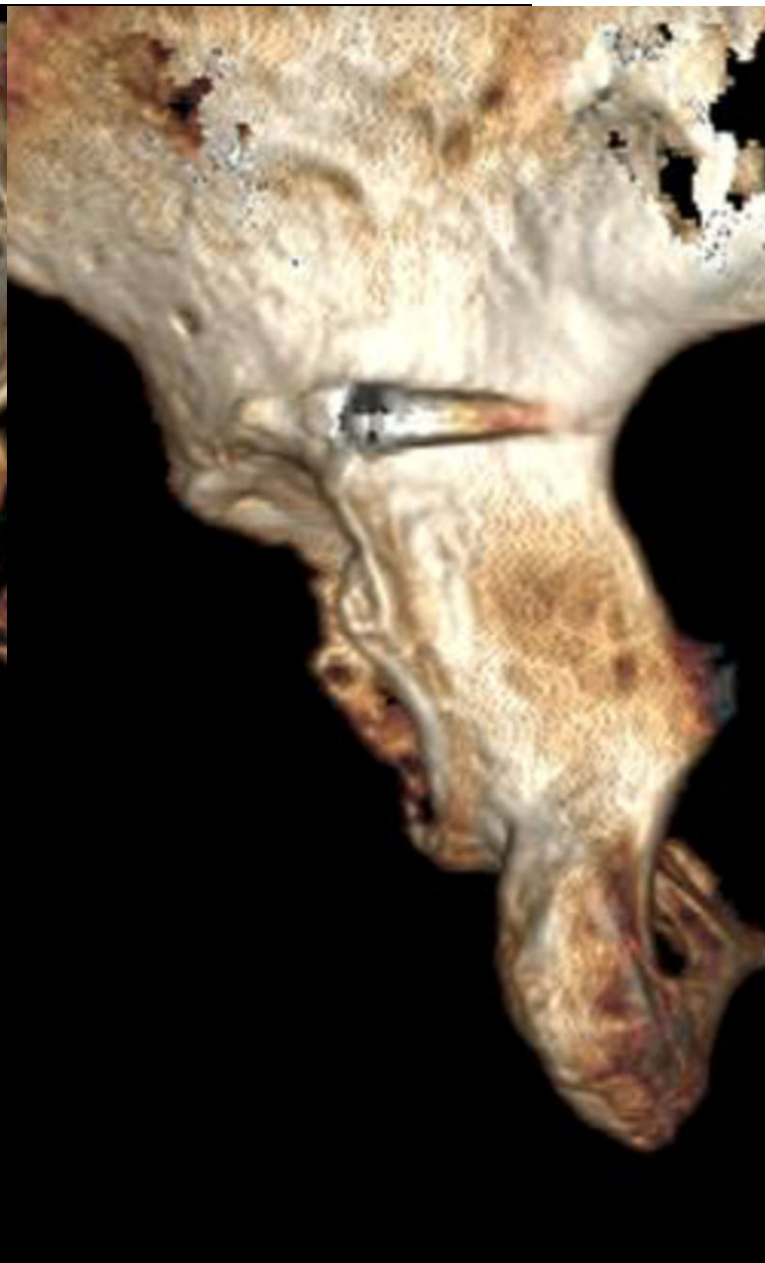
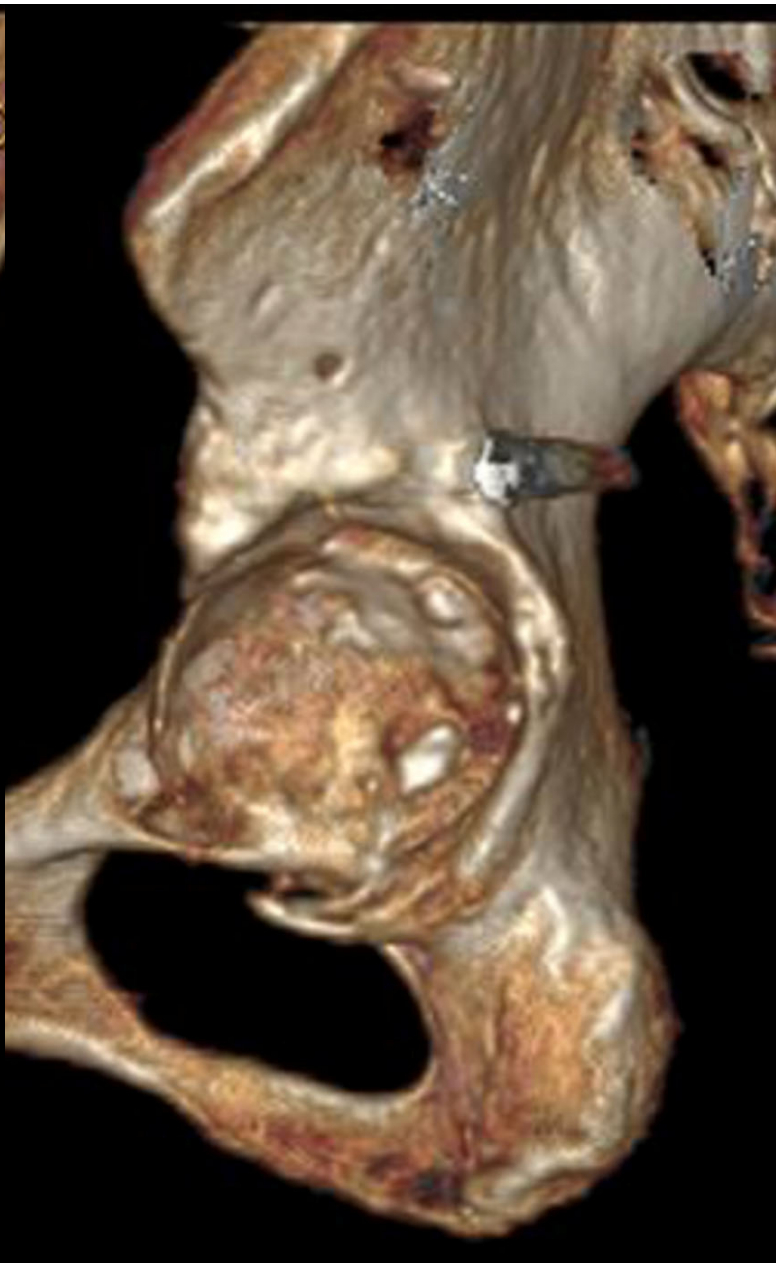
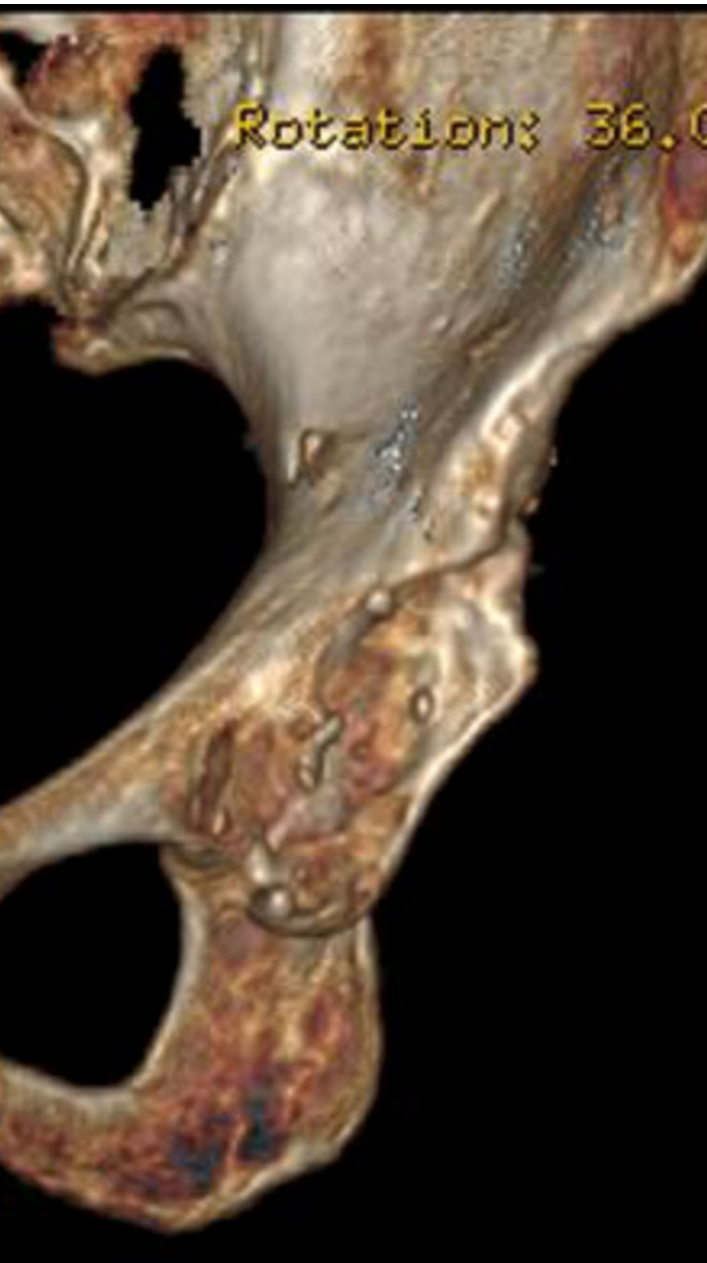






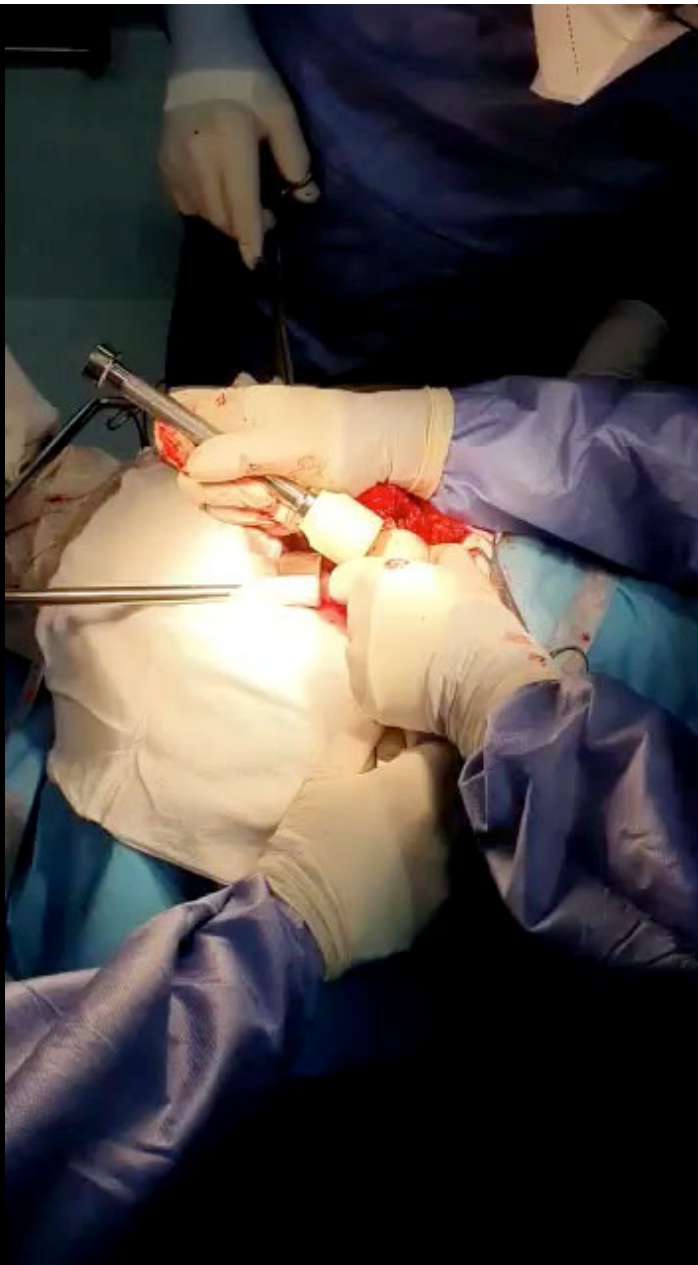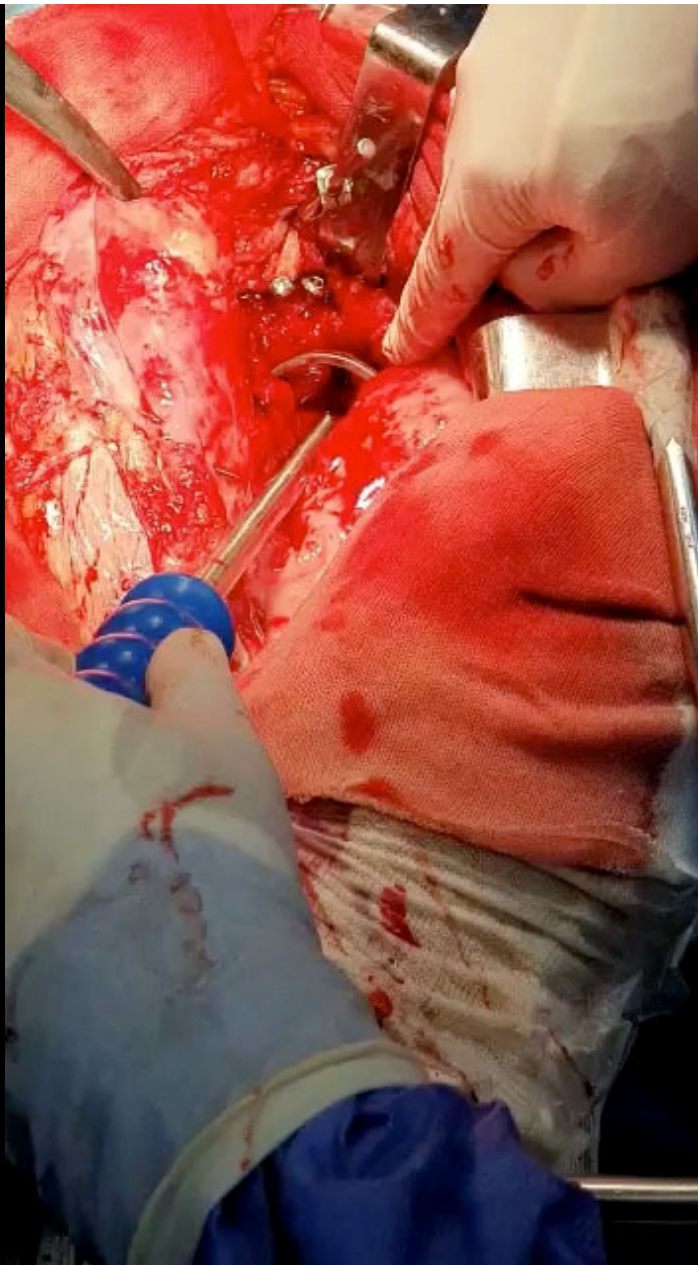**POP inmediato 1er tiempo: Retiro de prótesis +  
colocación de espaciador**

112007 500000000 5001001

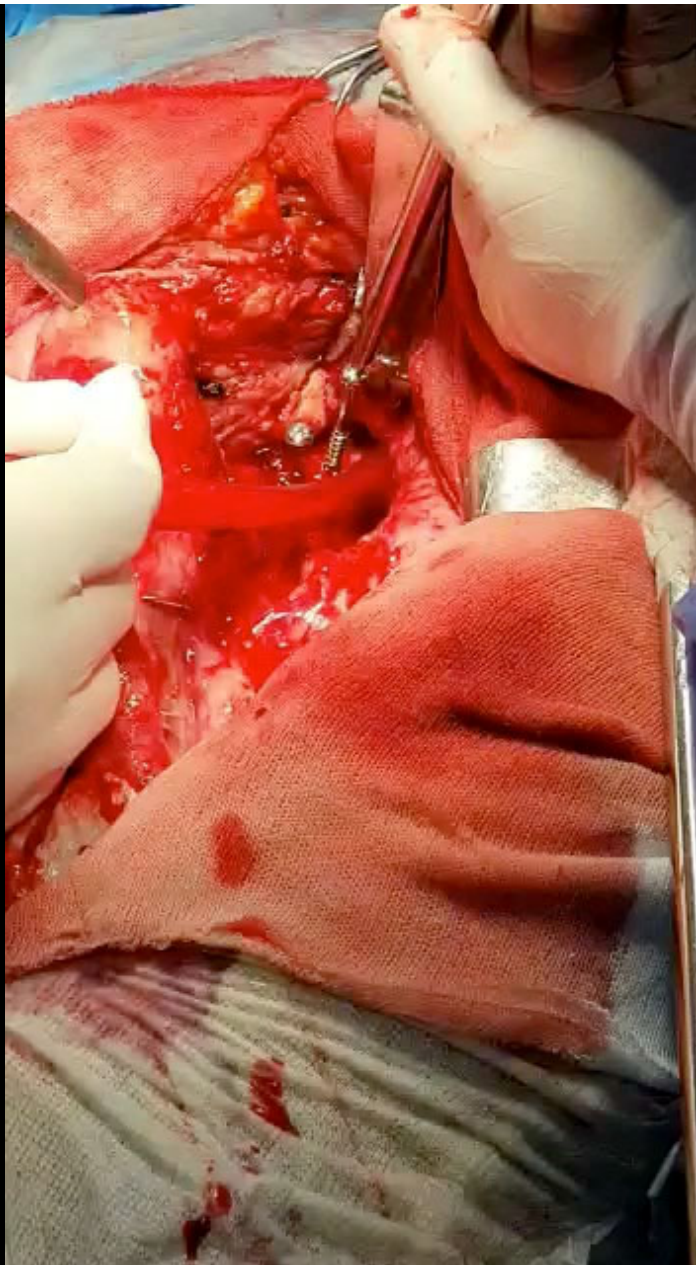


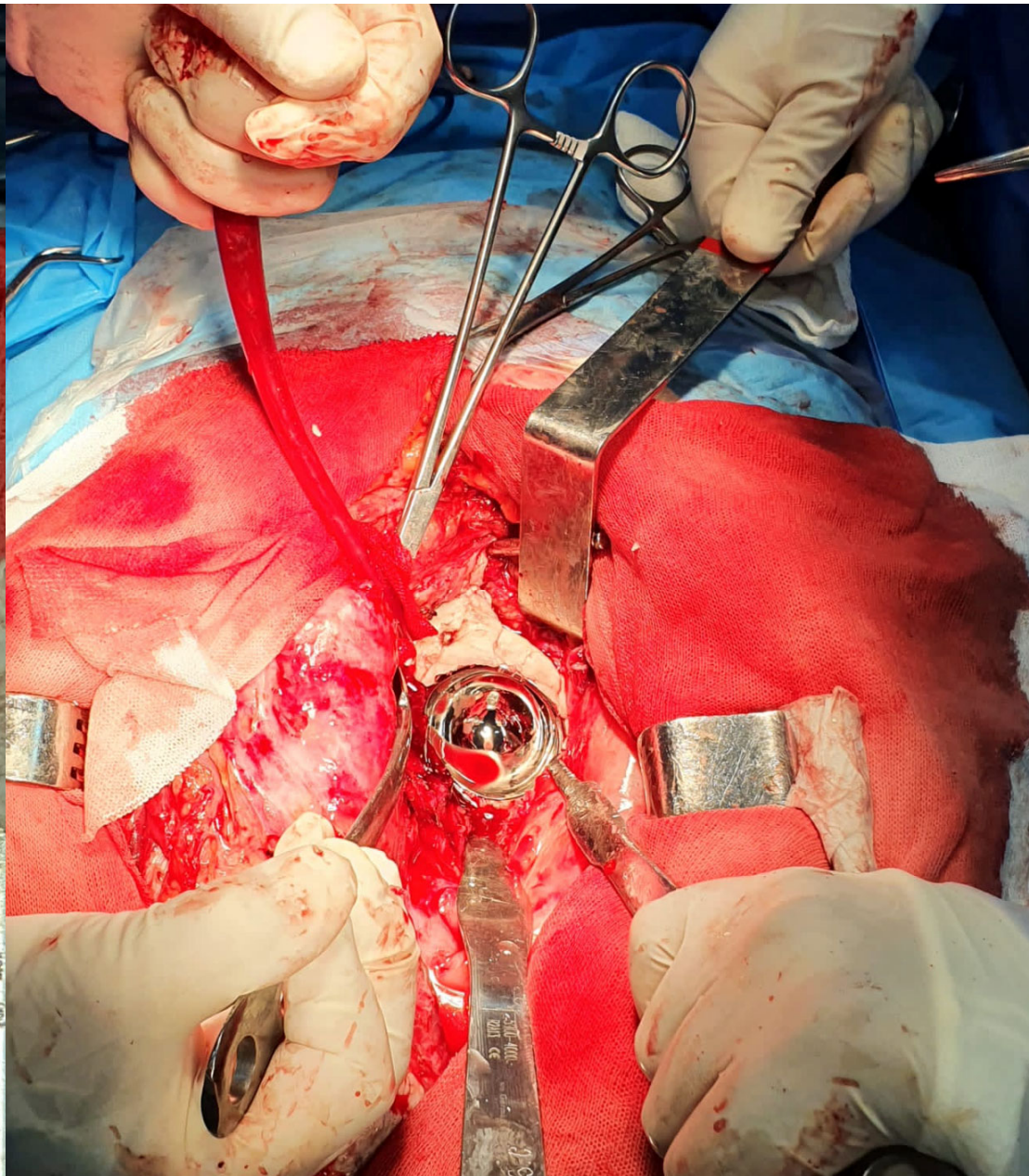
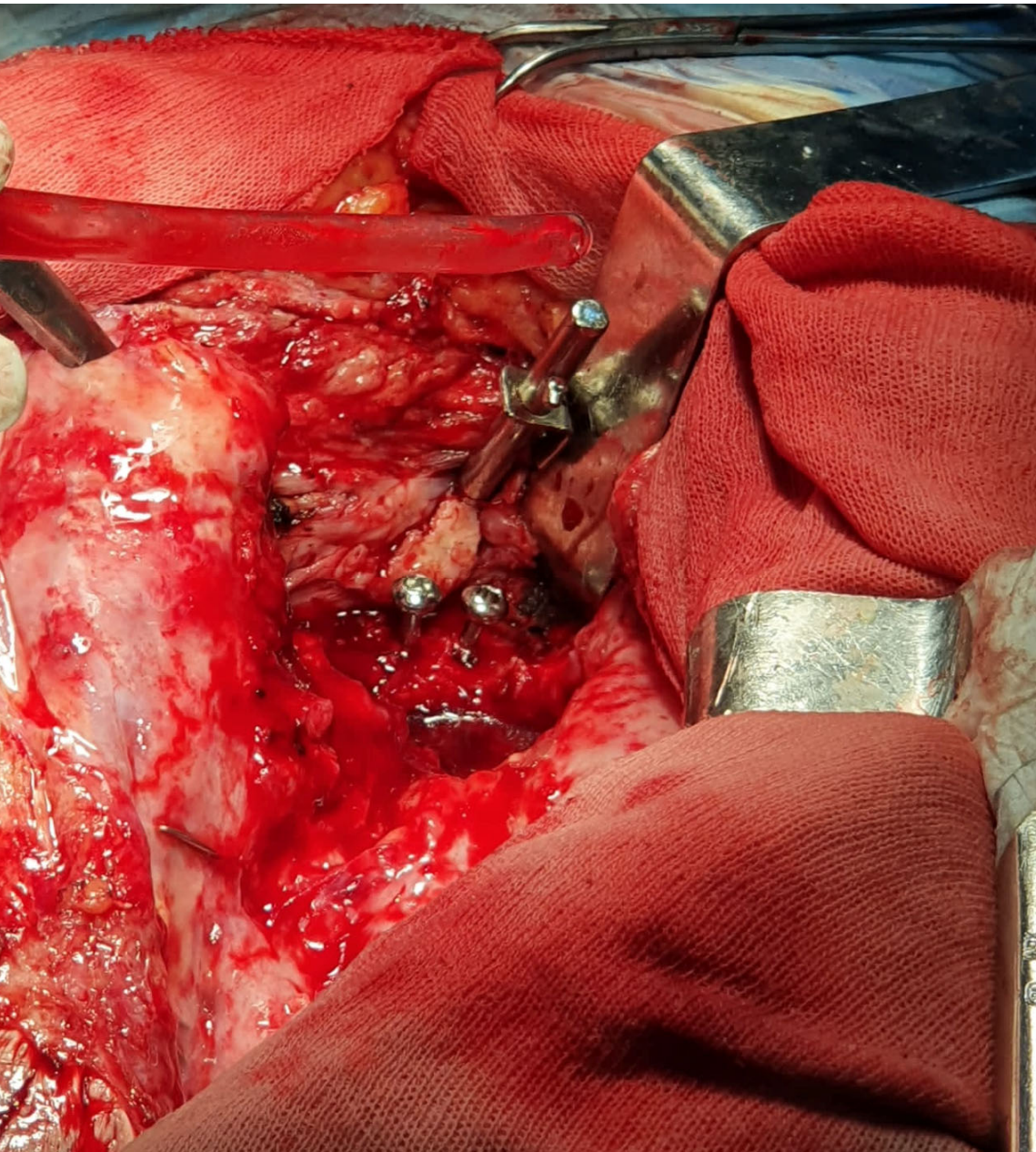


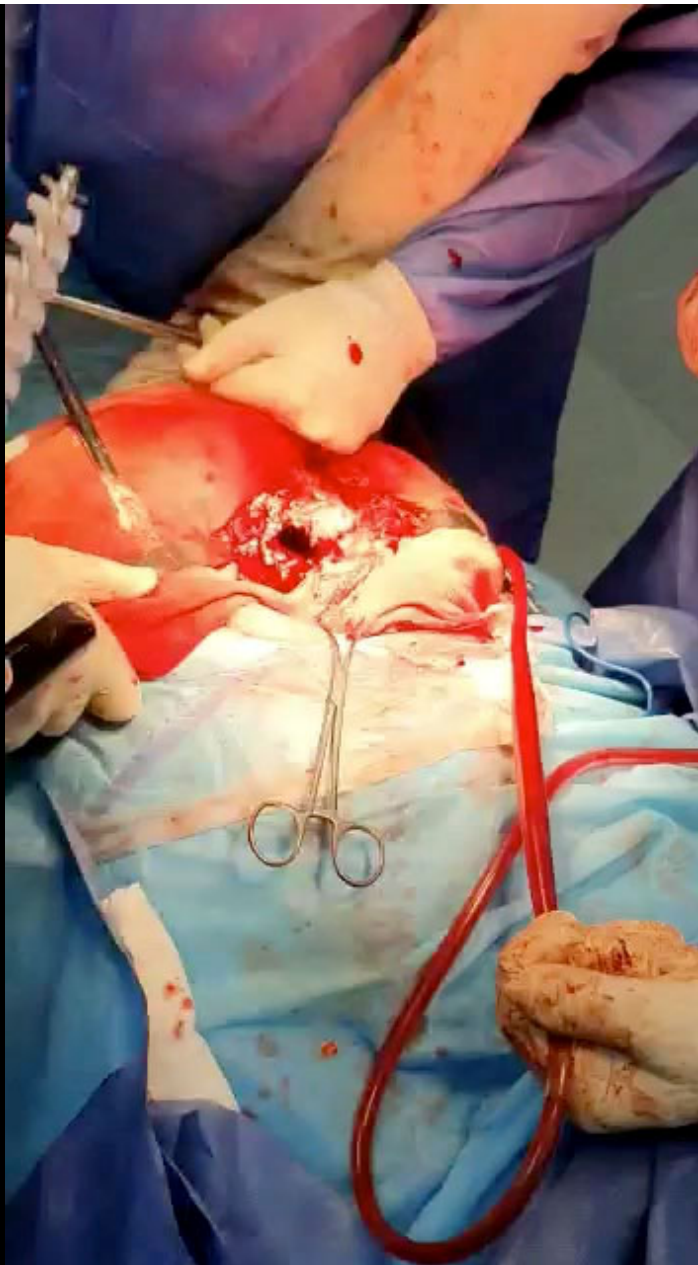




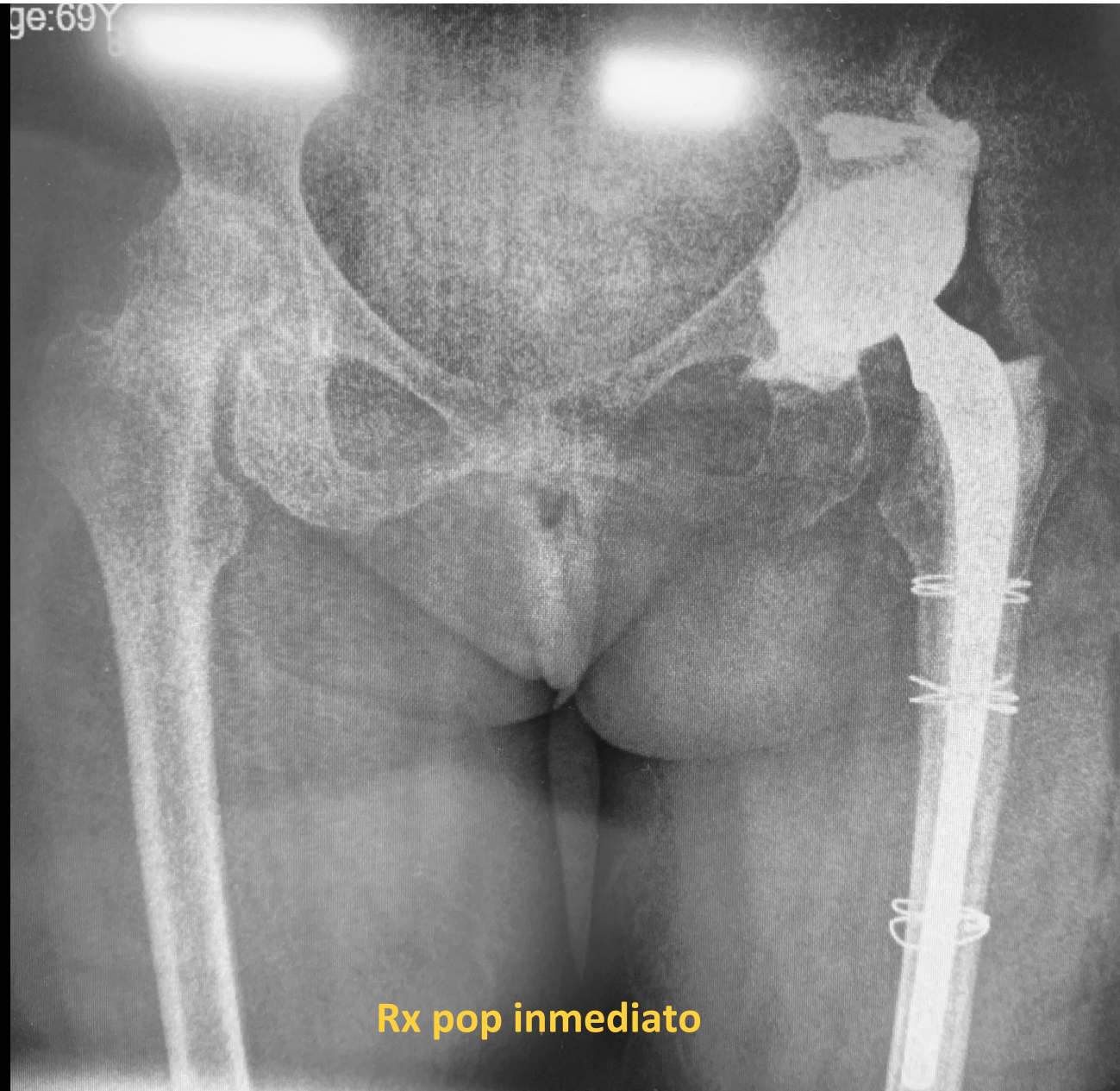







ge:69Y



**Rx pop inmediato**

UMERO, PELVIS, C

HAB.124.EP.30222842.P.069283

I

Rx pop

